

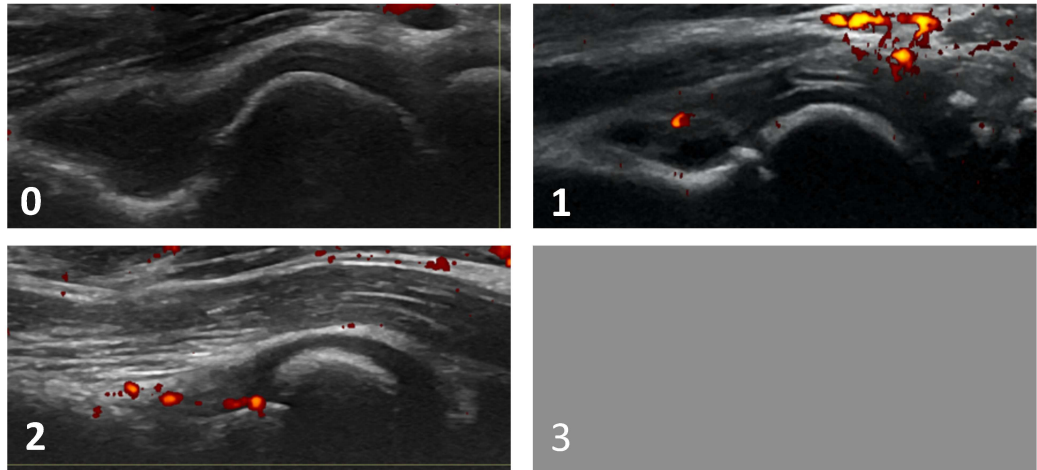
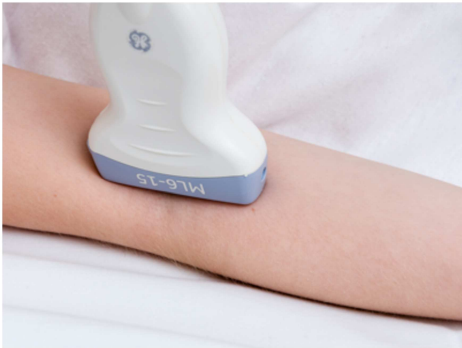Ultrasonographic atlas for scoring of power Doppler (PD) activity in patients with juvenile idiopathic arthritis

Nina Krafft Sande et al.

Included joint regions

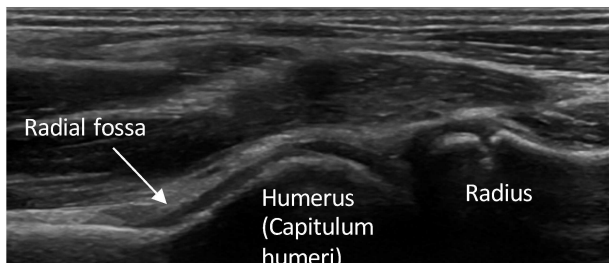
- Anterior elbow
- Posterior elbow
- Wrist (radiocarpal and midcarpal)
- Metacarpophalangeal (MCP) 2-3 dorsal
- Proximal interphalangeal (PIP) 2-3 dorsal
- Proximal interphalangeal (PIP) 2-3 volar
- Knee, suprapatellar recess
- Knee, lateral parapatellar recess
- Tibiotalar
- Talonavicular
- Anterior subtalar
- Posterior subtalar
- Metatarsophalangeal (MTP) 2-3 dorsal

Anterior elbow



The subject will be in a supine position, but the scanning can also be done with the subject on the parents' lap. The elbow should be in full extension and supination of the lower arm. A longitudinal anterior scan of the elbow (humeroradial) joint.

Landmarks: 1) the distal humerus and 2) the radius.



PD scoring for the anterior elbow, the humeroradial joint

0: No Doppler signal

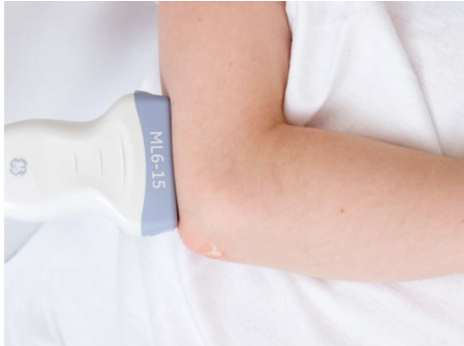1: 1-3 signals within the area of synovial hypertrophy only

2: > 3 signals or confluent signals present in < 50% of the area of synovial hypertrophy

3: Confluent signals present in > 50% of the area of synovial hypertrophy

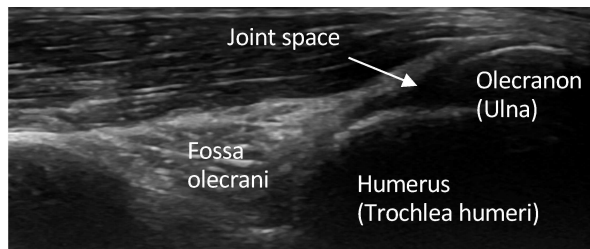
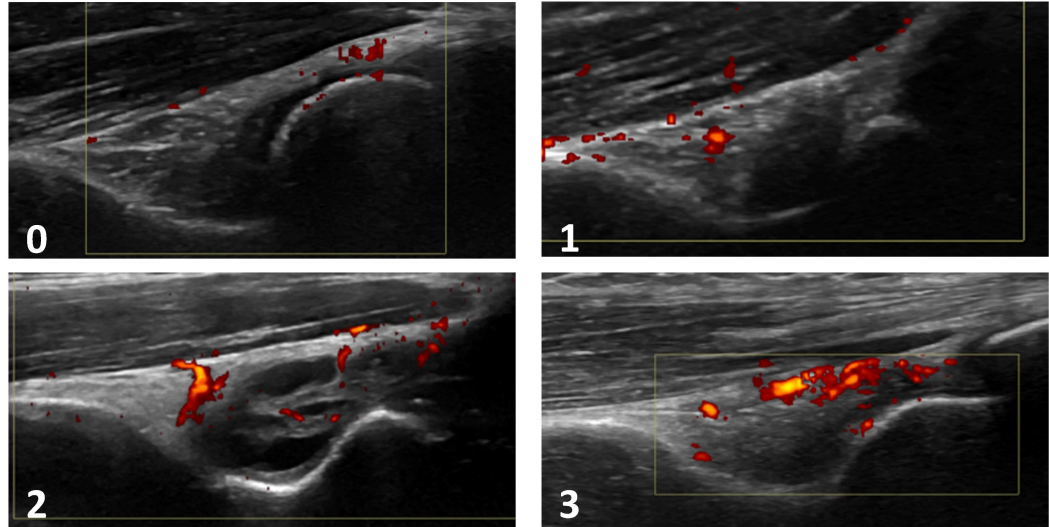
(Ting et al. 2019)

Posterior elbow



The subject will be in a supine position, but the scanning can also be done with the subject on the parents' lap. The elbow should be flexed at 90 degrees with the forearm resting on the stomach. A longitudinal posterior scan of the elbow (humeroulnar) joint.

Landmarks: 1) the distal humerus and 2) the olecranon (ulna).



PD scoring for the posterior elbow, the humeroulnar joint

0: No Doppler signal

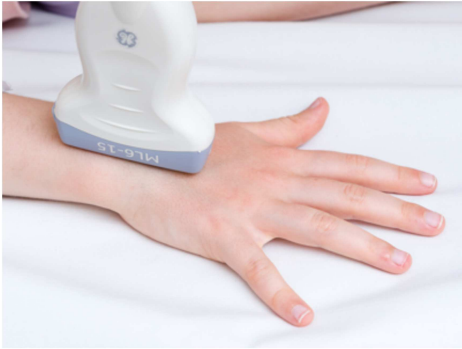1: 1-3 signals within the area of synovial hypertrophy only

2: > 3 signals or confluent signals present in < 50% of the area of synovial hypertrophy

3: Confluent signals present in > 50% of the area of synovial hypertrophy

(Ting et al. 2019)

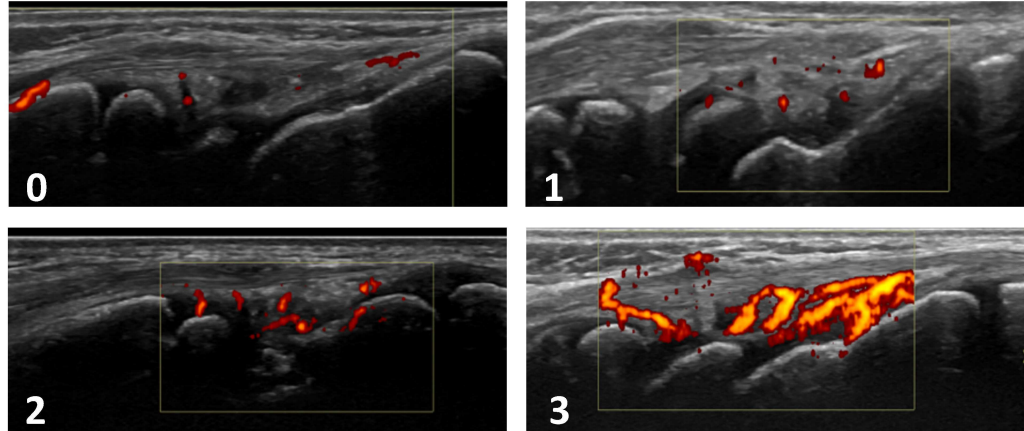
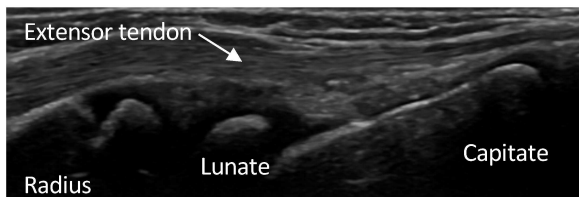Radiocarpal and midcarpal



The subject will be in a sitting position, the hands palm-side down in a neutral position on an examination table and resting the elbow on the table. A longitudinal dorsal scan of the radiocarpal and midcarpal joints at the sagittal midline of the wrist, including the distal radius, the lunate and the capitate bone.

Landmarks: 1) the distal end of diaphysis and epiphyseal cartilage of radius and 2) the dorsal recess of the radiocarpal and midcarpal joints and over them 3) a compartment of the extensor tendons according to the area imaged.

(Collado et al. 2016)



PD scoring for the radiocarpal and midcarpal joints

0: No Doppler signal

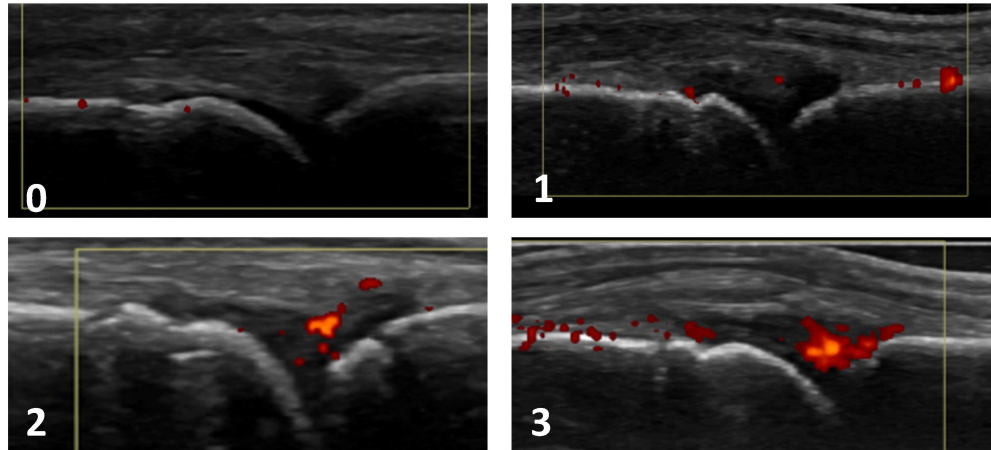
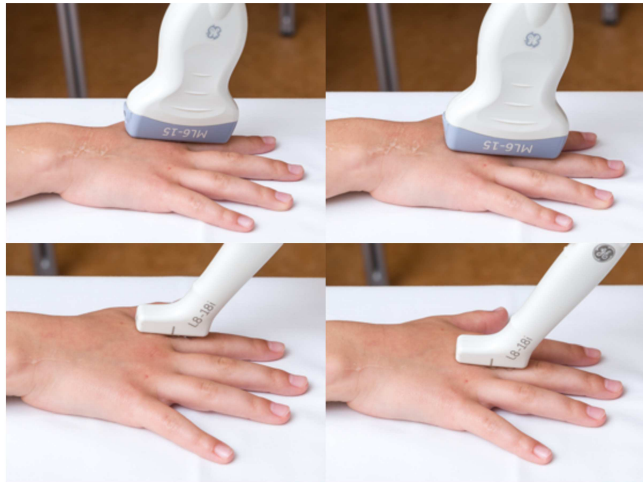1: 1-3 signals within the area of synovial hypertrophy only

2: > 3 signals or confluent signals present in < 50% of the area of synovial hypertrophy

3: Confluent signals present in > 50% of the area of synovial hypertrophy

(Ting et al. 2019)

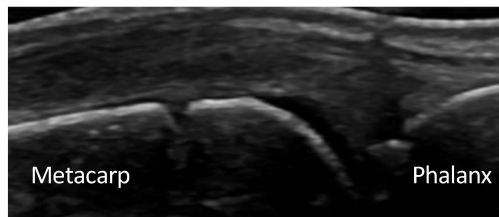
MCP2 - MCP3 dorsal



The subject will be in a sitting position with the hands palm-side down in a neutral position on an examination table.

A longitudinal dorsal scan of the MCP2 and MCP3 joints.

Landmarks: 1) the head of the metacarpal bone (2/3 of the image) and 2) the base of the proximal phalanx (1/3 of the image).



PD scoring for the MCP2 and MCP3 joints, dorsal

0: No Doppler signal

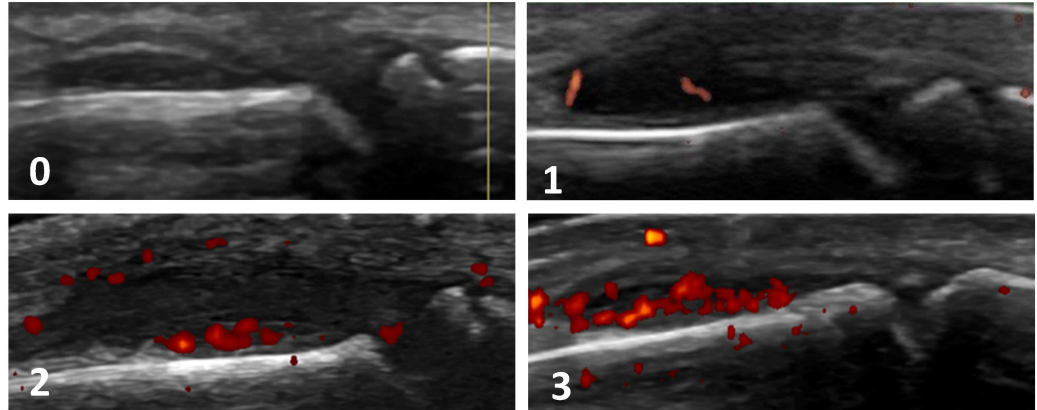
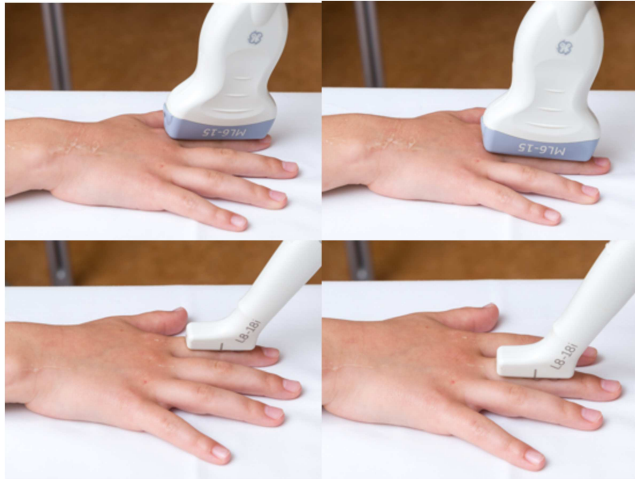1: 1-3 signals within the area of synovial hypertrophy only

2: > 3 signals or confluent signals present in < 50% of the area of synovial hypertrophy

3: Confluent signals present in > 50% of the area of synovial hypertrophy

(Ting et al. 2019)

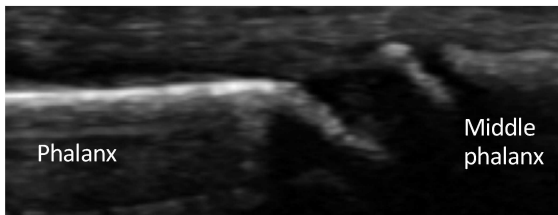
PIP2 - PIP3 dorsal



The subject will be in a sitting position with the hands palm-side down in a neutral position on an examination table.

A longitudinal dorsal scan of the PIP2 and PIP3 joints.

Landmarks: 1) the head of the proximal phalanx (2/3 of the image) and 2) the base of the middle phalanx (1/3 of the image).



PD scoring for the PIP2 and PIP3 joints, dorsal

0: No Doppler signal

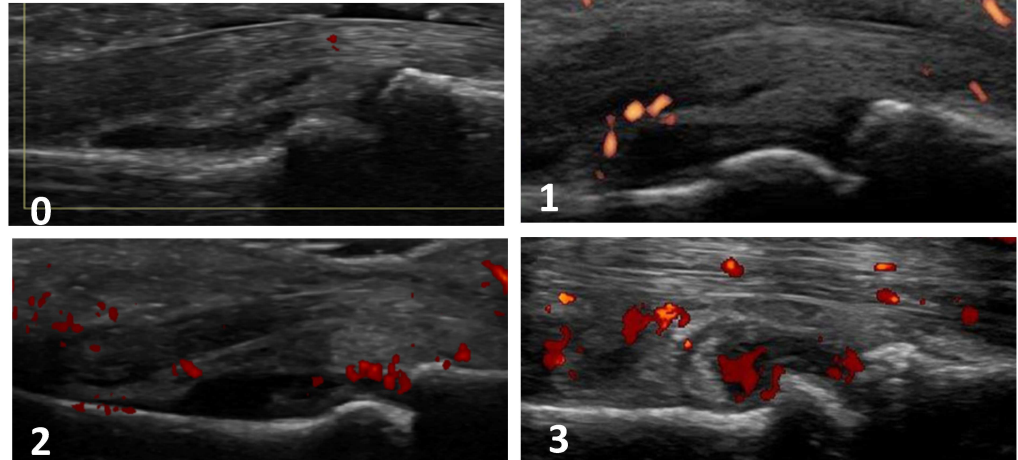
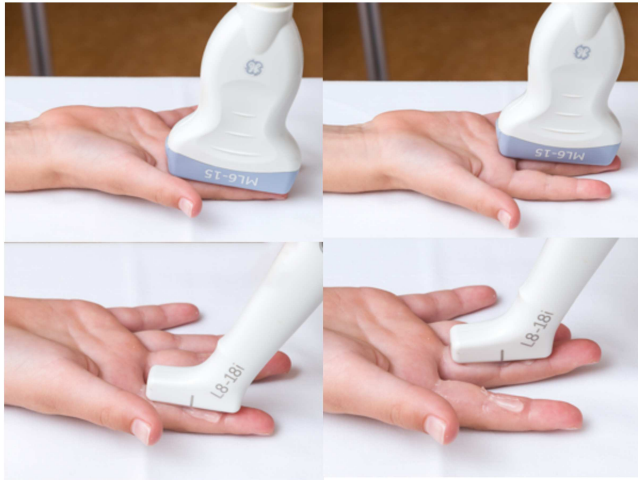1: 1-3 signals within the area of synovial hypertrophy only

2: > 3 signals or confluent signals present in < 50% of the area of synovial hypertrophy

3: Confluent signals present in > 50% of the area of synovial hypertrophy

(Ting et al. 2019)

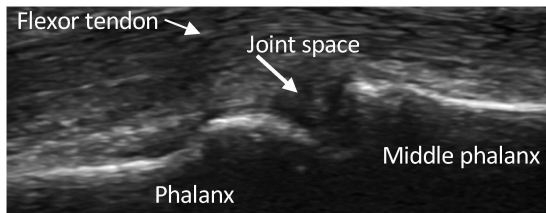
PIP2 - PIP3 volar



The subject will be in a sitting position with the hands palm-side up in a neutral position on an examination table.

A longitudinal volar scan of the PIP2 and PIP3 joints.

Landmarks: 1) the head of the proximal phalanx and 2) the base of the middle phalanx and 3) the flexor tendon.



PD scoring for the PIP2 and PIP3 joints, volar

0: No Doppler signal

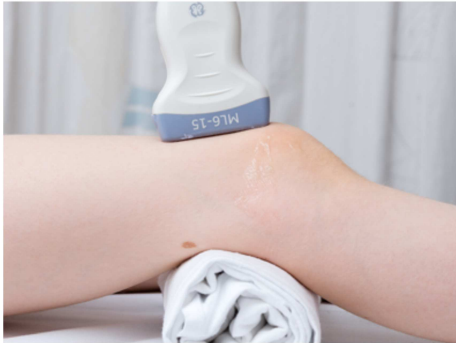1: 1-3 signals within the area of synovial hypertrophy only

2: > 3 signals or confluent signals present in < 50% of the area of synovial hypertrophy

3: Confluent signals present in > 50% of the area of synovial hypertrophy

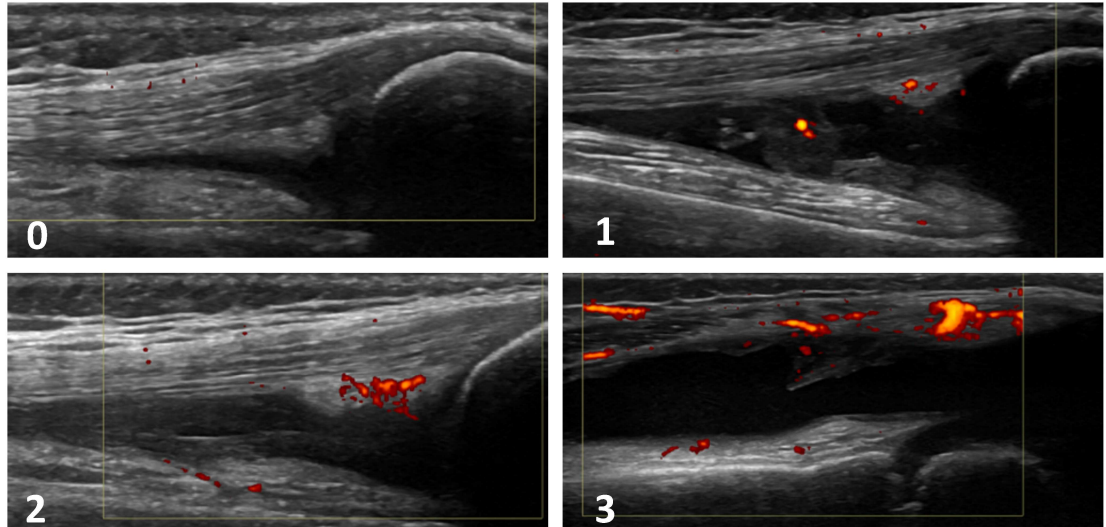
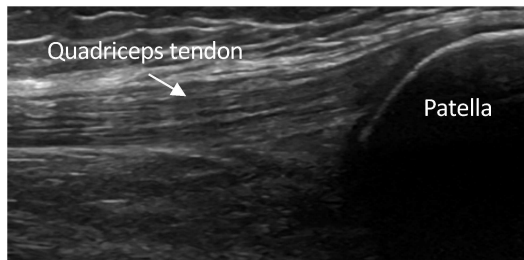
(Ting et al. 2019)

Knee, suprapatellar recess



The subject will be in a supine position. The knee should be flexed at 30 degrees, and images taken after the subject completes flexion and extension three times. A longitudinal scan of the suprapatellar joint space. For the youngest subjects, the patella should fill 1/3 of the image to compensate for the relatively shorter femur.

Landmarks: 1) the proximal third of the patella and 2) a clearly visualized quadriceps tendon.
(Ting et al. 2019)



PD scoring for the knee, suprapatellar recess

0: No Doppler signal

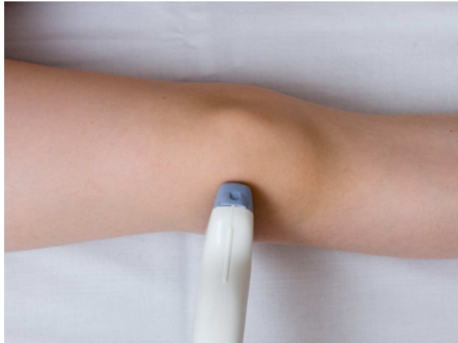1: 1-3 signals within the area of synovial hypertrophy only

2: > 3 signals or confluent signals present in < 50% of the area of synovial hypertrophy

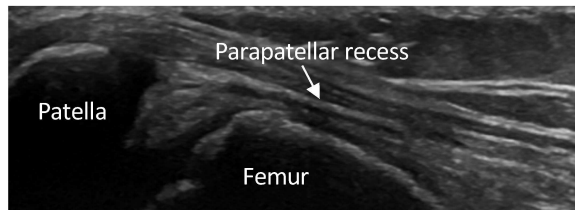
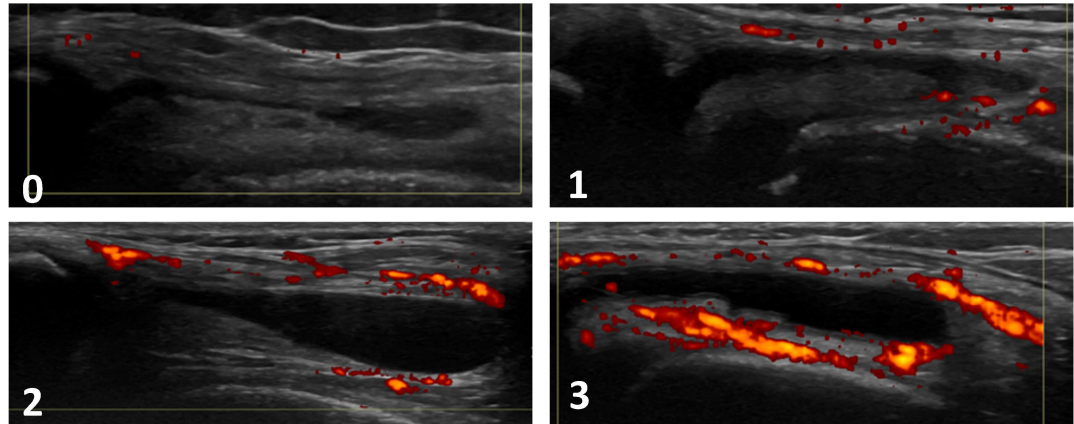
3: Confluent signals present in > 50% of the area of synovial hypertrophy

(Ting et al. 2019)

Knee, lateral parapatellar recess



The subject will be in a supine position. The knee should be flexed at 30 degrees. For the lateral parapatellar recess the image will be obtained with the probe in transverse position over the mid-patella with both the patella and femur in view.
Landmarks: 1) the superior edge of the patella and 2) the femoral condyle.
 (Ting et al. 2019)



PD scoring for the knee, lateral parapatellar recess

0: No Doppler signal

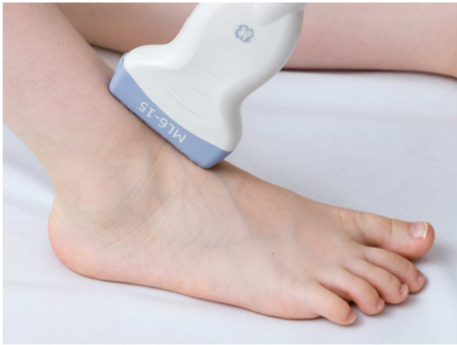1: 1-3 signals within the area of synovial hypertrophy only

2: > 3 signals or confluent signals present in < 50% of the area of synovial hypertrophy

3: Confluent signals present in > 50% of the area of synovial hypertrophy

(Ting et al. 2019)

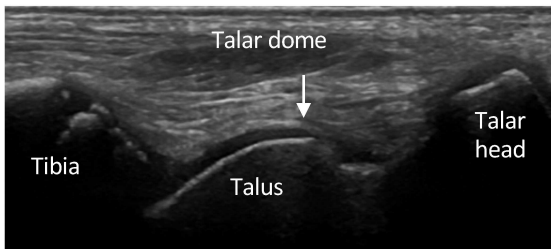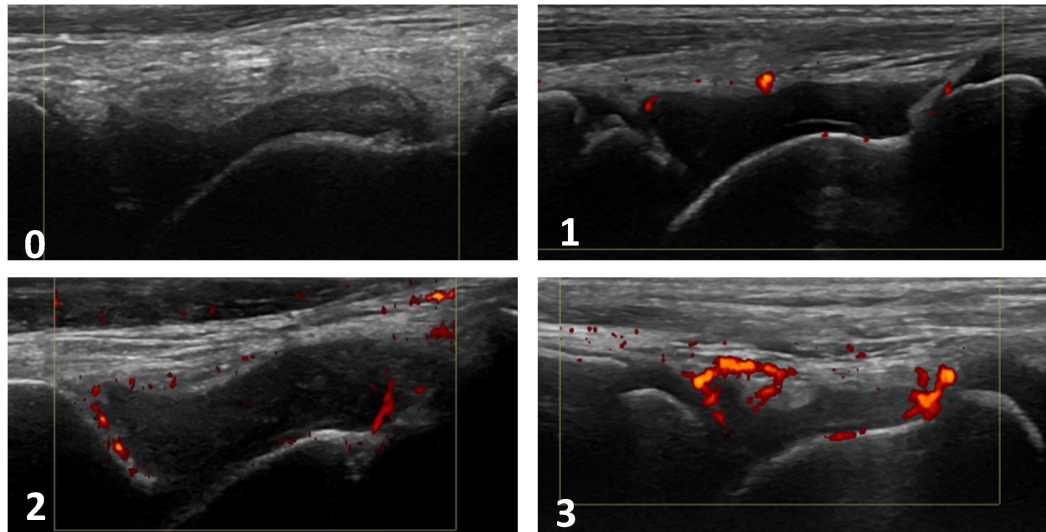
Tibiotalar



The subject will be in a supine position with the knee at 90 degrees flexion and the foot sole-side down.

A longitudinal scan of the tibiotalar joint.

Landmarks: 1) the distal end of the tibia and 2) the talus.



PD scoring for the tibiotalar joint

0: No Doppler signal

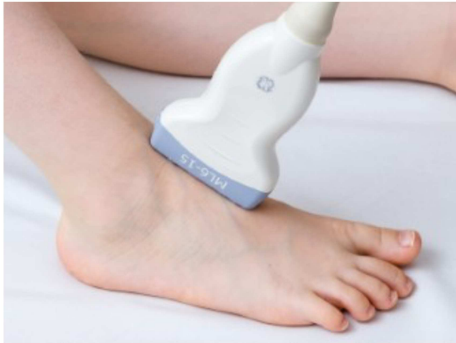1: 1-3 signals within the area of synovial hypertrophy only

2: > 3 signals or confluent signals present in < 50% of the area of synovial hypertrophy

3: Confluent signals present in > 50% of the area of synovial hypertrophy

(Ting et al. 2019)

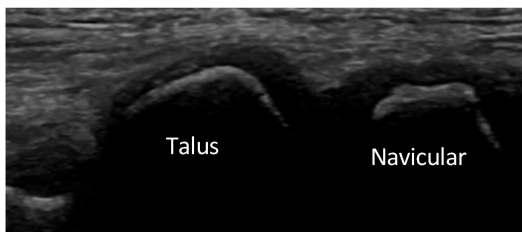
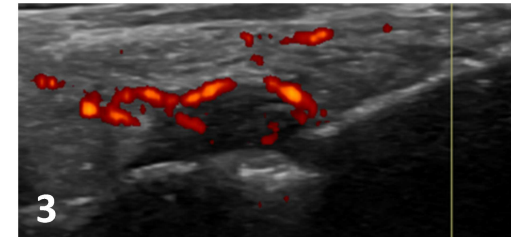
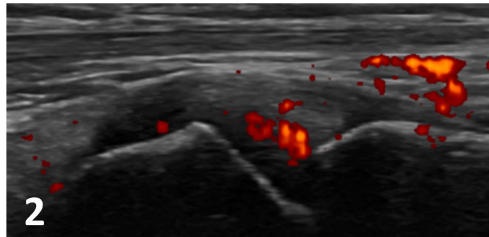
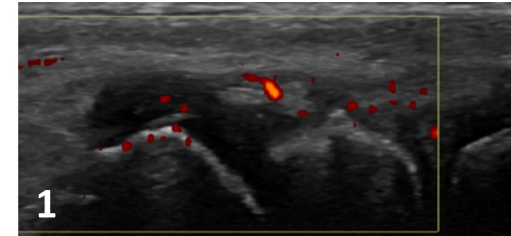
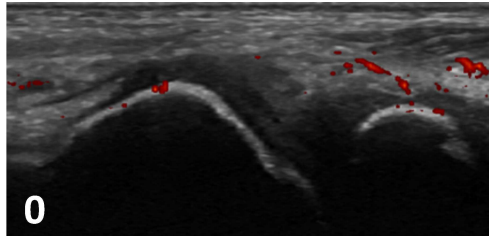
Talonavicular



The subject will be in a supine position with the knee at 90 degrees flexion and the foot sole-side down.

A longitudinal scan of the talonavicular joint.

Landmarks: 1) the talus and 2) the navicular bone.



PD scoring for the talonavicular joint

0: No Doppler signal

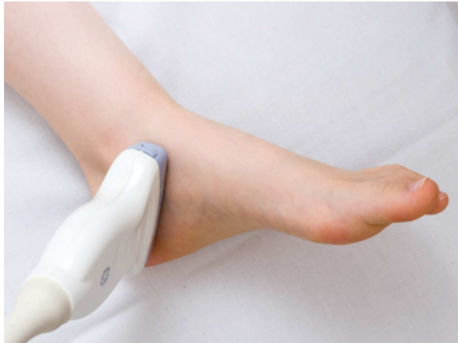1: 1-3 signals within the area of synovial hypertrophy only

2: > 3 signals or confluent signals present in < 50% of the area of synovial hypertrophy

3: Confluent signals present in > 50% of the area of synovial hypertrophy

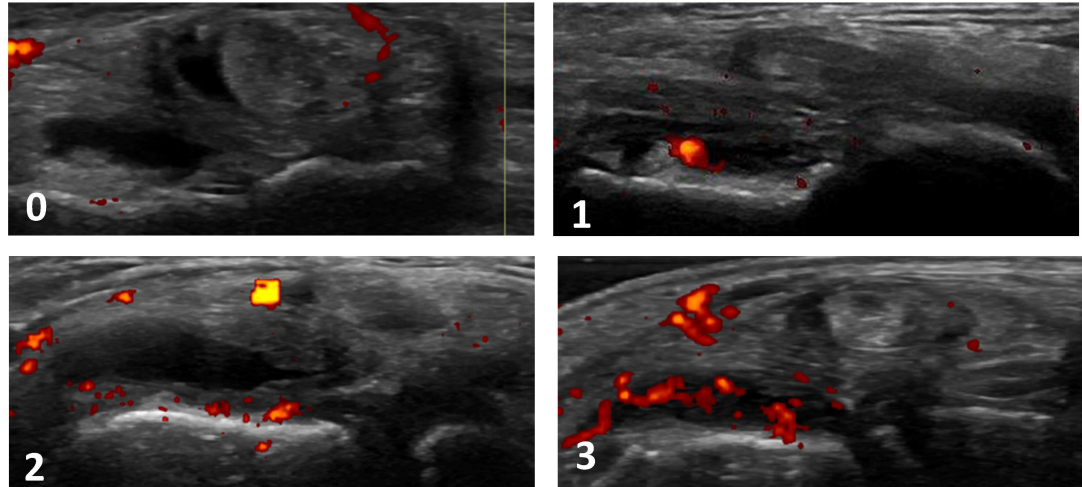
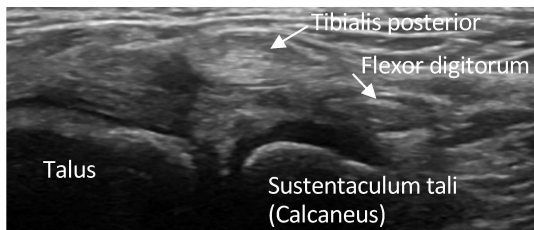
(Ting et al. 2019)

Anterior subtalar



The subject will be in a supine position with the leg straight and the forefoot/ankle in slight eversion. The probe will be positioned at 45 degrees pointing to the heel and then moved proximally and distally. A medial scan of the anterior subtalar joint.

Landmarks: 1) the talus and 2) the sustentaculum tali (calcaneus).



PD scoring for the anterior subtalar joint

0: No Doppler signal

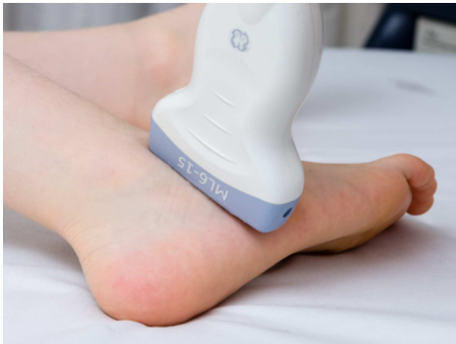1: 1-3 signals within the area of synovial hypertrophy only

2: > 3 signals or confluent signals present in < 50% of the area of synovial hypertrophy

3: Confluent signals present in > 50% of the area of synovial hypertrophy

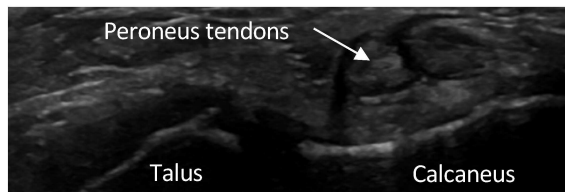
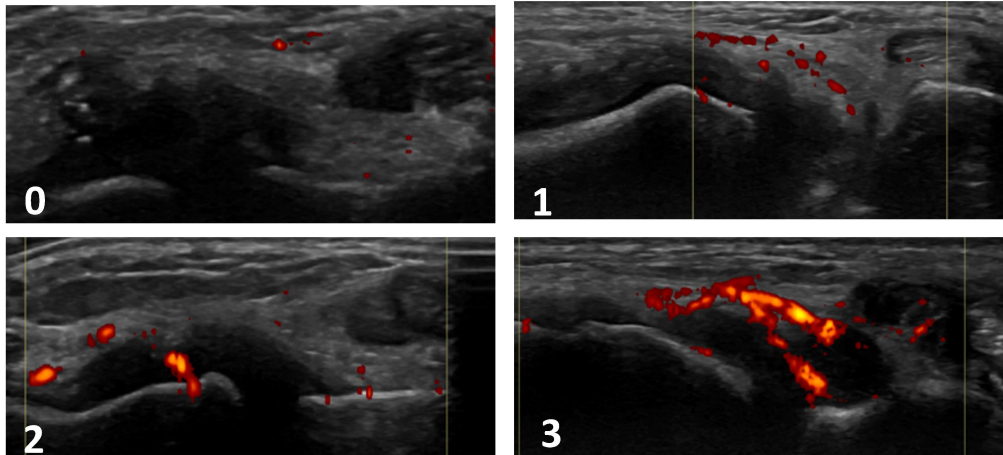
(Ting et al. 2019)

Posterior subtalar



The subject will be in a supine position with the leg straight and the forefoot/ankle in slight inversion. The probe will be positioned along the sinus tarsi perpendicular to the sole, and then moved posteriorly. If no distension is seen, the image will be taken visualizing the joint with the peroneus tendons. A lateral scan of the posterior subtalar joint.

Landmarks: 1) the talus and 2) the calcaneus.



PD scoring for the posterior subtalar joint

0: No Doppler signal

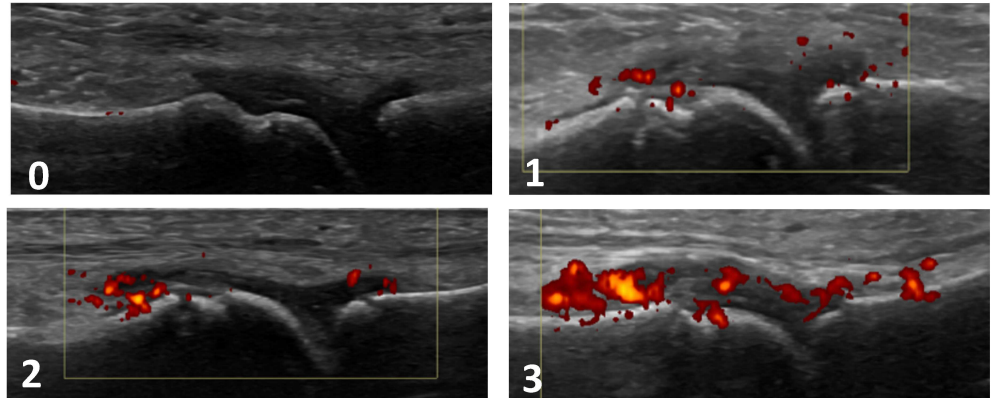
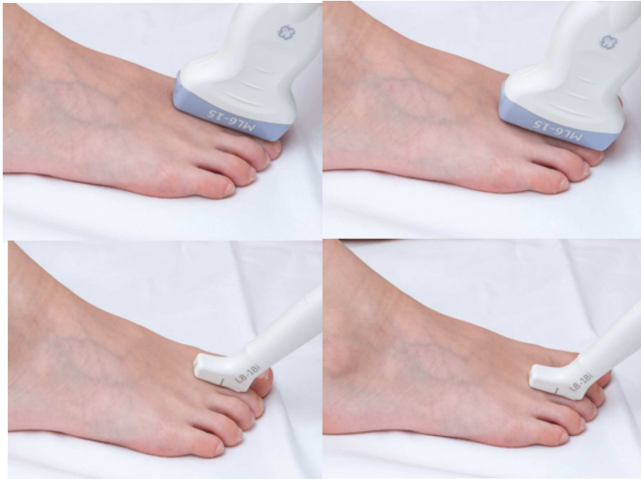1: 1-3 signals within the area of synovial hypertrophy only

2: > 3 signals or confluent signals present in < 50% of the area of synovial hypertrophy

3: Confluent signals present in > 50% of the area of synovial hypertrophy

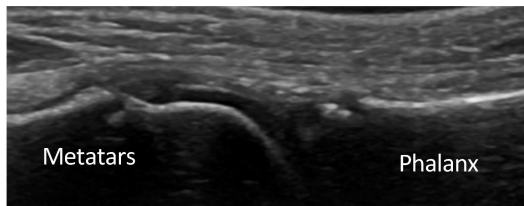
(Ting et al. 2019)

MTP2 - MTP3 dorsal



The subject will be in a supine position with the knee at 90 degrees flexion and the foot sole-side down. A longitudinal dorsal scan of the MTP2 and MTP3 joints.

Landmarks: 1) the head of the metatarsal bone (2/3 of the image) and 2) the base of the proximal phalanx (1/3 of the image).



PD scoring for the MTP2 and MTP3 joints, dorsal

0: No Doppler signal

1: 1-3 signals within the area of synovial hypertrophy only

2: > 3 signals or confluent signals present in < 50% of the area of synovial hypertrophy

3: Confluent signals present in > 50% of the area of synovial hypertrophy

(Ting et al. 2019)